


RESENTING CLINICAL SIGNS

DATE History: Focal left-sided murmur. Pre-anesthetic evaluation.

ECHOCARDIOGRAPHIC FINDINGS

2D, M-mode, and Doppler study.

PERFORMED BY:

Dr. Meredith Swart

INTERPRETED BY

Keith Blass, DVM,
MS, DACVIM
(Cardiology)

There is mild left atrial dilation. The mitral valve leaflets are thickened and exhibit systolic prolapse. There is Doppler evidence of mitral regurgitation present. There is very mild left ventricular dilation. Left ventricular systolic function is mildly hyperdynamic. The aorta and aortic valve are normal. Right atrial and right ventricular dimensions are normal. The tricuspid valve leaflets are mildly thickened, and there is Doppler evidence of tricuspid regurgitation present. TR velocity does not suggest the presence of pulmonary hypertension. The pulmonary artery and pulmonic valve are normal. No shunting lesions are visualized. No pericardial effusion or cardiac masses are seen.

PATIENT

Tucker Wilcox

LA - 34.4 mm
LVIDd - 31.1 mm
LVIDs - 17.4 mm
FS - 44%
RA - 19.6 mm
LVOT - 1.50 m/s
RVOT - 1.13 m/s
TR - 2.21 m/s

SPECIES

Canine

ASSESSMENT/RECOMMENDATIONS

Degenerative mitral and tricuspid valve disease

BREED

Terrier Mix

This examination demonstrates regurgitation of blood across Tucker's mitral valve resulting from degenerative valve disease. Tucker's tricuspid valve disease is mild, and appears to be well-compensated at this time. His mitral valve disease is a bit more advanced, as Tucker has mild dilation of his left atrium and very mild dilation of his left ventricle, though his left ventricular systolic function is well-preserved. As only mild left heart chamber dilation is present, Tucker's current risk for the development of clinical signs secondary to his disease, such as coughing, exercise intolerance, syncope, and labored breathing, appears to be relatively low, though careful monitoring for these signs is recommended.

SEX

MN

AGE

13 y

Tucker's cardiovascular risk for general anesthesia is mildly increased based on this exam, therefore, some precautions should be taken in order to minimize this risk. I recommend avoiding the use of alpha-2 agonists, ketamine, and telazol in the anesthetic protocol, as well as reducing the IV fluid rate by at least 25%. If possible, monitoring of heart rhythm, blood pressure, and pulse oximetry are recommended during the procedure.

WEIGHT

21 lb

I recommend starting Tucker on pimobendan (2.5 mg BID), as this medication should help to slow the progression of his mitral valve disease, as well as reduce his risk for general anesthesia.

A recheck echocardiogram is recommended in 9 months. Thoracic radiographs are recommended if Tucker experiences respiratory clinical signs.

HOSPITAL NAME

Swart Veterinary
Imaging

REFERRING VET

Dr. Swart



DATE

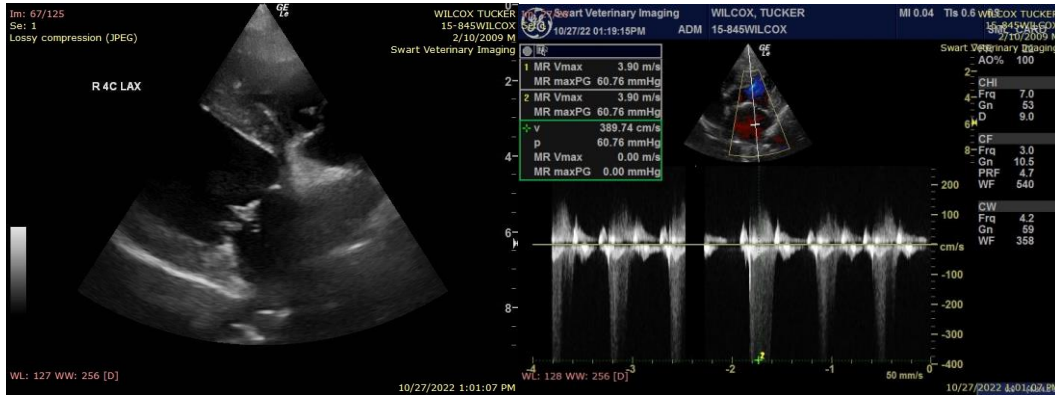
10/27/22

PERFORMED BY:

Dr. Meredith Swart

INTERPRETED BY

Keith Blass, DVM,
MS, DACVIM
(Cardiology)



The information and recommendations provided are based on the images presented by the referring veterinarian. No evaluation can be communicated regarding pathology that was not visible in the image/video clips provided.

PATIENT

Tucker Wilcox

Thank you for this referral. If the clinical or image interpretation does not parallel your findings or if I can be of any further assistance please contact me.

SPECIES

Canine

Keith Blass, DVM, MS, DACVIM (Cardiology)
KeithBlass@gmail.com
631-804-5754

BREED

Terrier Mix

SEX

MN

AGE

13 y

WEIGHT

21 lb

HOSPITAL NAME

Swart Veterinary
Imaging

REFERRING VET

Dr. Swart